

Simultaneous Prosthetic Mitral Valve and Pacemaker Lead Endocarditis: A Case Report

*Abdulrahman Naser

Department. of Cardiology, Kırklareli training and research hospital, Kırklareli, Türkiye

ARTICLE INFO

Type: Case Report

Received: 25 October, 2024

Accepted: 26 December, 2024

*Corresponding Author:

E-mail address:

abdulrahman_naser@hotmail.com

To cite this article: Naser A. Simultaneous Prosthetic Mitral Valve and Pacemaker Lead Endocarditis: A Case Report..

Afghanistan Journal of Basic Medical Sciences. 2025 Jan 2(1): 121-124.

<https://doi.org/10.62134/khatamuni.65>

ABSTRACT

Infective endocarditis (IE) is a life-threatening disease that usually affects a single heart valve. However, multi-valvular IE, either two-sided or one-sided is rarely reported. IE concomitantly affecting a left-sided heart valve and pacemaker lead is almost never defined, recently. Here, we present a 59-year-old, 69 kg, 158 cm Caucasian female patient who presented with stroke, mainly left-sided IE clinic, diagnosed simultaneously with prosthetic valve endocarditis (PVE) and cardiac device-related infective endocarditis (CDRIE).

Keywords: Infective endocarditis, Mitral prosthetic valve, Cardiac pacemaker

Introduction

Infective endocarditis (IE), is a rare and life-threatening infectious disease that occurs on the endocardial surface of the heart. It still maintains its importance due to its high mortality rate. The estimated incidence of IE is reported as 13.8 cases per 100,000 people per year, and IE was responsible for 66,300 deaths worldwide in 2019 (1, 2).

The development of IE generally requires the presence of predisposing risk factors, pathogens entering the bloodstream, and the adequacy of the host's immune response. Patient groups with a previous history of endocarditis, congenital heart disease, valvular heart disease, prosthetic valves, intra-cardiac device such as ventricular assist

devices, and central venous or arterial catheter, intravenous drug abuse, chronic hemodialysis, solid organ and hematopoietic stem cell transplantation are at high risk for infective endocarditis (1, 2).

Diagnosing IE early and starting effective treatment is very important in reducing mortality and morbidity rates. The diagnosis of IE is based on a clinical suspicion supported by consistent microbiological data and the documentation of IE-related cardiac lesions through imaging techniques (1, 2). In individuals with predisposing risk factors for IE, IE should be considered in cases of unexplained fever, malaise, weight loss, increase in acute phase reactants, unexplained

arterial embolization including those to the central nervous system and lungs, unexplained heart failure and valve insufficiency, and unexplained blood culture positivity. Transthoracic echocardiography (TTE) and transesophageal echocardiography (TOE) are the first-line and key diagnostic imaging techniques for IE. Vegetation, abscess, pseudoaneurysm or intracardiac fistula, valve aneurysm or perforation, new partial dehiscence of prosthetic valve and significantly increasing valve insufficiency are the main echocardiographic findings for the diagnosis (1, 2).

Infective endocarditis generally affects a single heart valve (3). However, there are case reports of both two-sided or one-sided multi-valvular IE (3,4). IE affect both a prosthetic heart valve and a pacemaker lead at the same time is almost never defined in the literature. In this case report, we present a patient who presented with stroke, predominantly left-sided IE, and was simultaneously diagnosed with prosthetic valve endocarditis (PVE) and cardiac device-related infective endocarditis (CDRIE).

Case report

A 59-year-old, 69 kg, 158 cm Caucasian female patient with underlying heart failure and a metallic prosthetic mitral valve was replaced 3 years prior to the presentation. In addition, she had undergone a gamma knife

procedure due to intracranial AVM, two years ago. The patient had a cardiac resynchronization therapy (CRT) device implanted on 08 Aug 2021. Since then, she had been admitted multiple times to the emergency services due to fever and general state disorders. Finally, on 11 Nov 2021 the patient was admitted to the ICU of our hospital with stroke and fever (39.3 °C).

No fluctuation, warmth, redness, or swelling of the skin over the generator pocket was observed. Dental and fundus examinations were normal. The patient denied a history of illicit drug use. Lab work showed leukocytosis=15.14K/ul, hematocrit=28.8%, hemoglobin=9 g/dl, procalcitonin 23.27 ng/mL, CRP=334.0mg/L, INR=2.9, albumin=2,5g/dl, glucose =159, creatinine=1.4mg/dl and eGFR = 47.13mL/min. Blood cultures were collected. Multi-slice non-contrast cranial CT scan performed during neurological evaluation showed widespread subacute infarct areas that were compatible with septic embolic infarction.

Based on these findings, cardiology consultation was requested, with suspicion of IE. TTE) and TOE were performed, revealed vegetations on prosthetic mitral valve (18x12 mm) and pacemaker lead (19x7 mm) at the right atrial level (Figure 1). The video will be sent to the respected readers in case of reasonable application via the corresponding author.

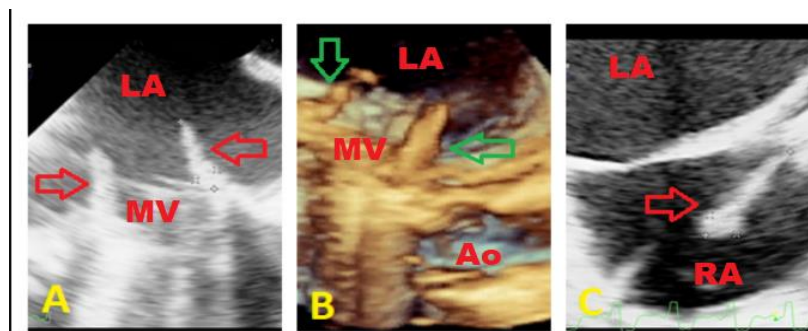


Figure 1: Transesophageal echocardiography demonstrating, A; Vegetations on prosthetic mitral valve (Red arrow), B; 3D-TOE of vegetations on mitral valve (Green arrow), C; Vegetation on pacemaker lead in right atrium (Red arrow). Ao; Aort, LA: left atrium, MV; Mitral valve, RA; right atrium.

Complete hardware removal and prosthetic valve surgery were recommended, but the patient and her relatives refused the operation. The serial blood cultures were positive for methicillin-susceptible *Staphylococcus aureus*, treatment with vancomycin and meropenem was initiated.

Discussion

Two-sided IE in the mean of right and left-sided valvular IE or a left-sided valvular IE and CDRIE is uncommon with higher risk of complications compared to single-valve IE. PVE, is the most severe form of IE, its incidence reported as 0.3%-1.2% per patient-years. The presence of the prosthetic heart valve or ring is the most predisposing conditions for IE (2). CDRIE is defined as an infection extending to the electrode leads, cardiac valve leaflets or endocardial surface and account for 10% of all IE (2, 5). It commonly occurs within the right atrium at the contact point of the leads to the endocardium and mostly affect tricuspid valve (2). Its usual manifestations are fever, bacteremia, and septic pulmonary emboli, which may manifest as chest pain, cough, or hemoptysis. In our case, the tricuspid valve was unaffected despite CDRIE, but PVE, a higher predisposing condition for IE, was occurred. Definite CDRIE and concomitant left-sided valvular IE is the rarest pattern of IE. Six cases (2 patients with MV-IE, 3 with AV-IE, and 1 with mitral and aortic valve IE) were reported out of 559 patients diagnosed at the time of surgery for 2 patients and on the basis of echocardiography for 4 patients. Clinical presentation is variable and frequently atypical in two-sided IE (1, 6). Sensitivity of Duke criteria is lower in this form of IE (1). Its diagnosis is based mainly on the results of echocardiography and blood cultures, as well as radiological techniques, particularly ^{18}F -FDG PET/CT (7).

Staphylococcus sp. was isolated in the blood sample of our patient, the most isolated microorganism in these entities.

Echocardiography, (TTE or TOE) is the technique of choice for the diagnosis of IE and plays a pivotal role in the management and monitoring of IE (1, 2). When TOE and TTE are used together, they detect vegetation in up to 90% of cases and are also useful in identifying regurgitation and abscess (8). In our patient, a bedside TTE found no clue about vegetations, but subsequently performed TOE observed the pacemaker lead and prosthetic mitral valve vegetations. However, prosthetic mitral valve vegetation alone was explanatory for the cerebral manifestation, considering the presence of a pacemaker and performing a comprehensive TOE revealed the lead vegetation as well. Although, established therapeutic option in PVE is still debated, surgery is generally the required option with lower in-hospital and 1-year mortality (9). Conversely, percutaneous extraction of the system is the recommended method for CDRIE (1). Surgery was recommended as the first-choice treatment, not accepted by our patient.

The presence of CDRIE and left-sided valvular IE is possible, and suspicion of CDRIE is crucial in the presence of the pacemaker lead, even in the absence of specific manifestation. Thus, comprehensive radiological especially echocardiographic evaluation is mandatory in case of multiple substrates for IE development.

Informed consent

An informed consent was obtained from the patient for publication of case details. All the procedures performed were in accordance with the ethical Declaration of Helsinki.

Conflict of interest

The author declares that there is no conflict of interests.

References

1. Victoria Delgado, Nina Ajmone Marsan, Suzanne de Waha, et al. 2023 ESC Guidelines for the management of endocarditis. *Eur Heart J.* 2023; 44(39):3948-4042. <https://doi.org/10.1093/eurheartj/ehad193>
2. Şimşek Yavuz S, Akar AR, Aydoğdu S, et al. [Diagnosis, treatment and prevention of infective endocarditis: Turkish consensus report]. *Klimik Derg.* 2019; 32(Suppl. 1): 2-116. Turkish.
3. Nemati M, Galang K, Min Jung S. Right and left-sided infective endocarditis in an IV drug abuser. *J Community Hosp Intern Med Perspect.* 2020;10(5):475-479 .
4. López J, Revilla A, Vilacosta I, et al. Multiple-valve infective endocarditis: clinical, microbiologic, echocardiographic, and prognostic profile. *Medicine (Baltimore).* 2011;90(4):231-236.
5. Sohail MR, Uslan DZ, Khan AH, Friedman PA, Hayes DL, Wilson WR, et al. Management and outcome of permanent pacemaker and implantable cardioverter-defibrillator infections. *J Am Coll Cardiol* 2007;49:1851–1859.
6. Xavier Duval, Christine Selton Suty, François Alla, Michèle Salvador-Mazenq, Yvette Bernard, Michèle Weber et al. Endocarditis in Patients with a Permanent Pacemaker: A 1-Year Epidemiological Survey on Infective Endocarditis due to Valvular and/or Pacemaker Infection. *Clin Infect Dis.* 2004;39(1):68-74.
7. Saby L, Laas O, Habib G, Cammilleri S, Mancini J, Tessonier L, et al. Positron emission tomography/computed tomography for diagnosis of prosthetic valve endocarditis: increased valvular 18F-fluorodeoxyglucose uptake as a novel major criterion. *J Am Coll Cardiol* 2013;61:2374–2382.
8. Molnar A, Sacui D, Manole S, Radulescu A, Beyer R. The value of transthoracic and transesophageal echocardiography for the diagnosis of the native aortic infective endocarditis valve complications: a case report and literature review. *Med Ultrason.* 2016;18(2):253-6.
9. Kiefer T, Park L, Tribouilloy C, Cortes C, Casillo R, Chu V, et al. Association between valvular surgery and mortality among patients with infective endocarditis complicated by heart failure. *JAMA* 2011;306:2239–2247.